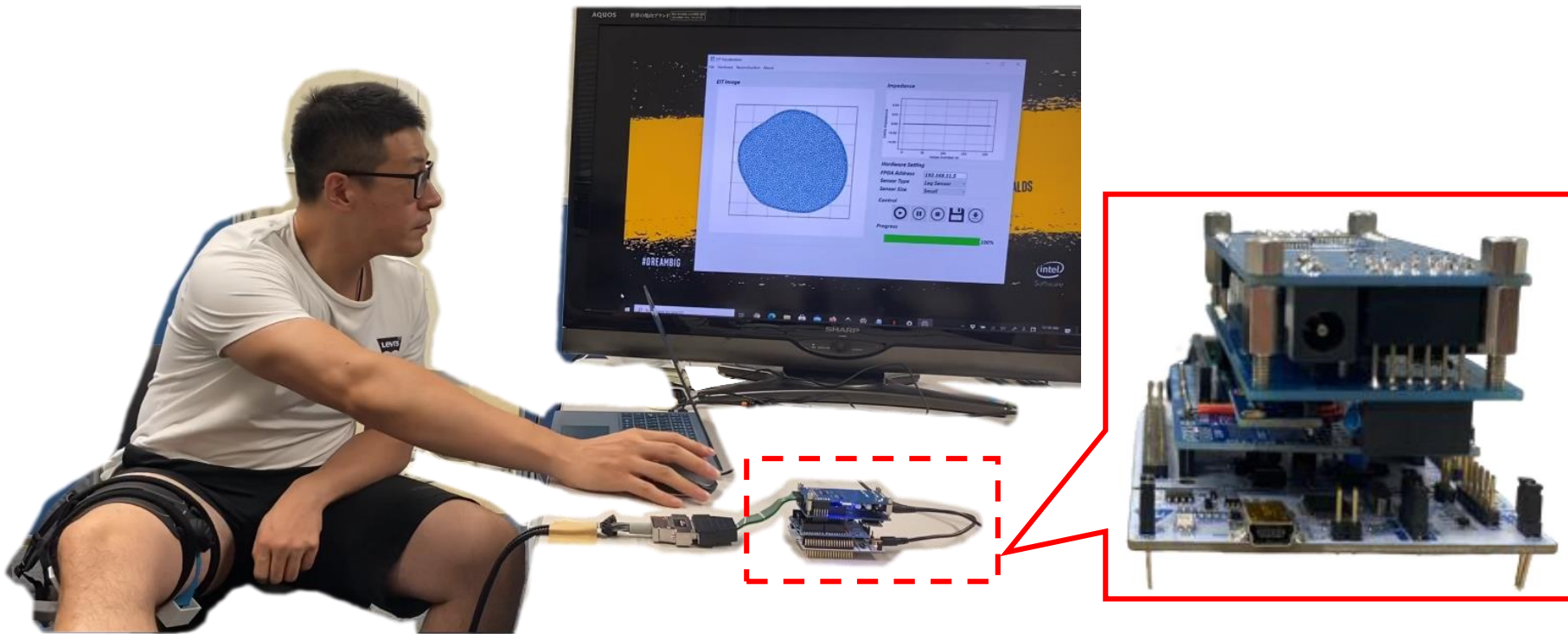
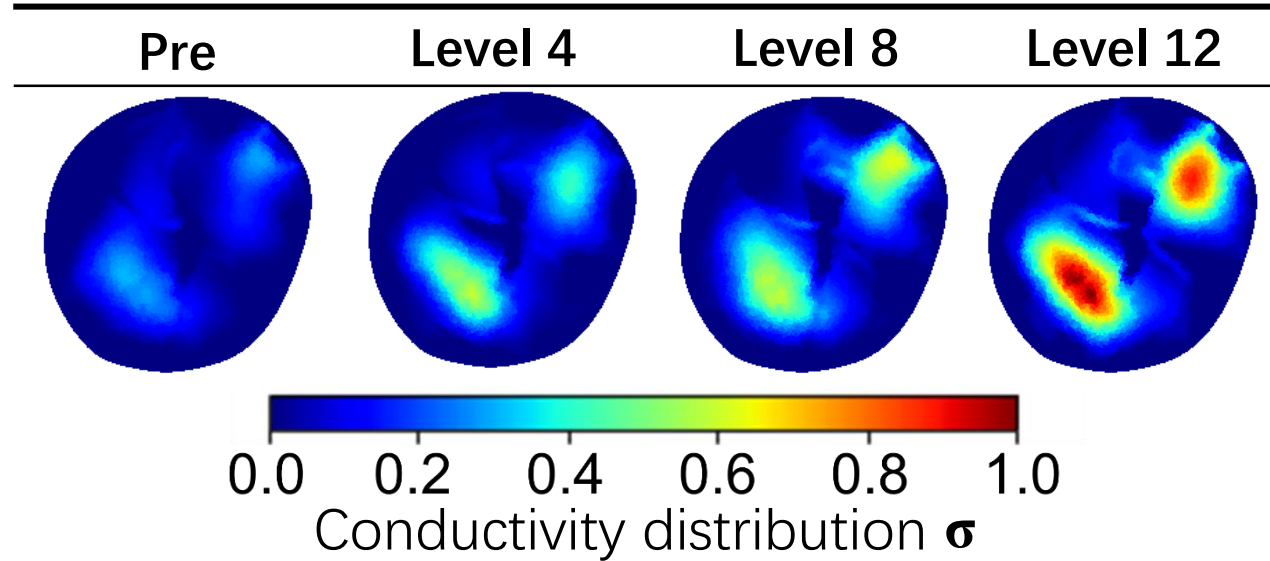
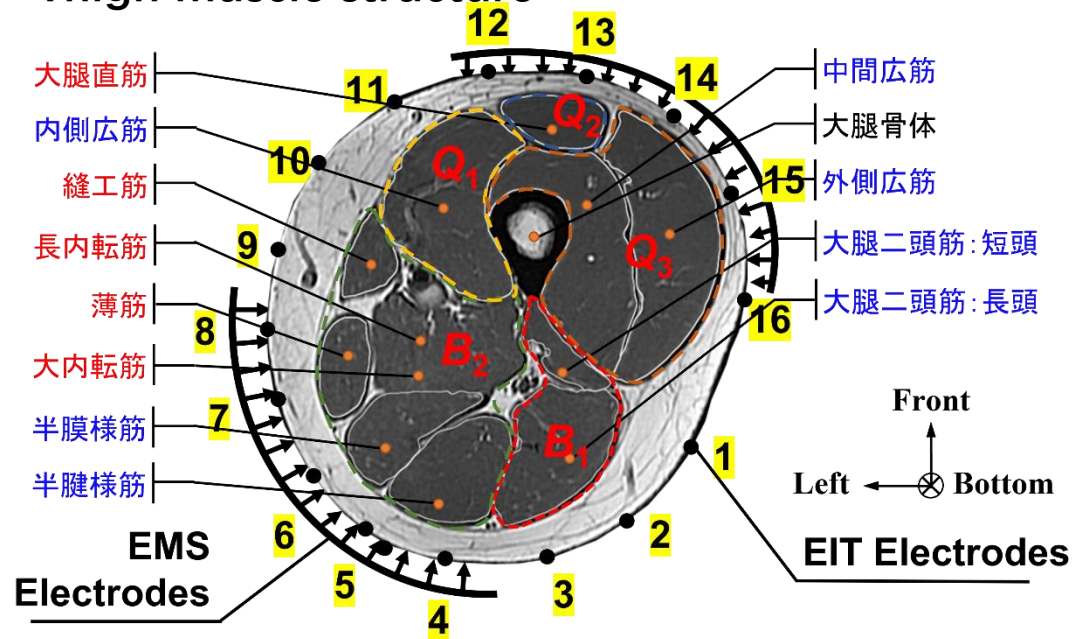


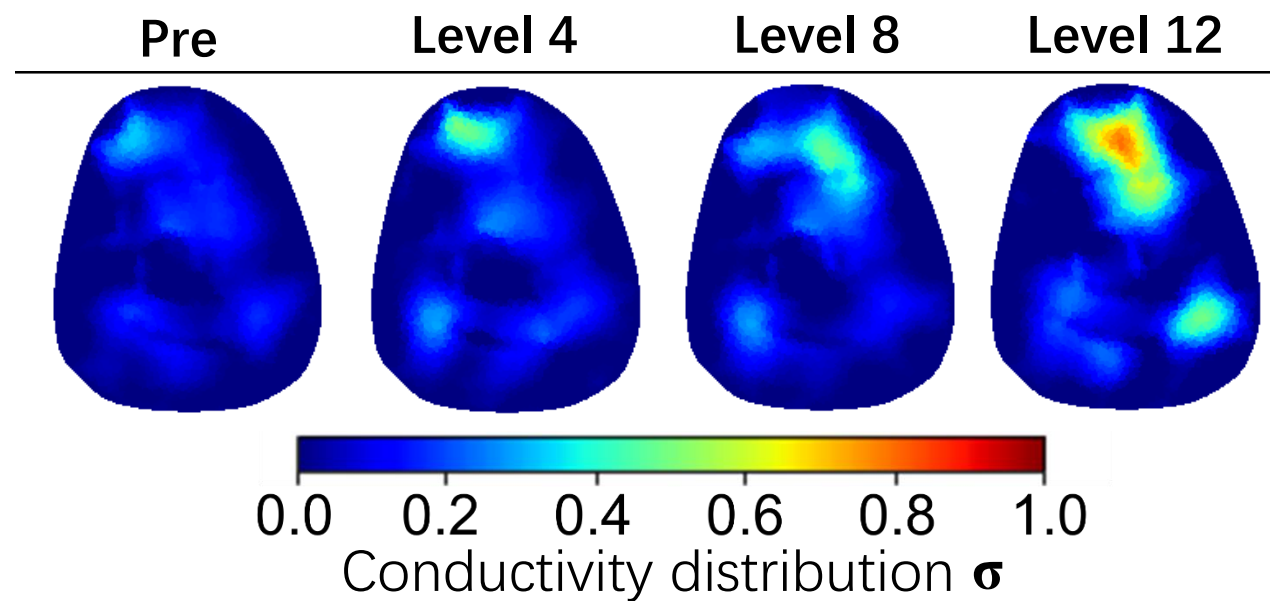
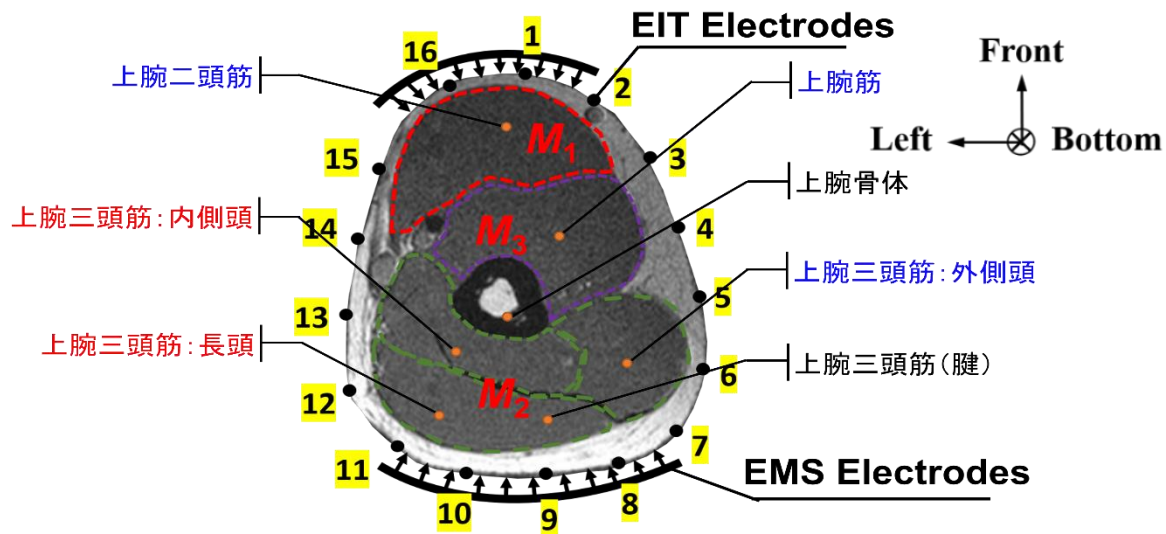
「筋肉・脂肪の可視化アルゴリズムの構築に関する研究」



❖ Thigh muscle structure



❖ Upper arm muscle structure



Type I: Red muscle fiber Type II: White muscle fiber